

=====CASE REPORT=====

The Importance of Treating Patients and not Images in the Management of Chronic Back and Leg Pain

Joseph A Costello Jr. DC, DABCO
Chief of Clinical Services, Avicenna Laser Technology, Inc

HISTORY:

This patient is a 37 year old female from Munich, Germany who has suffered with chronic back and leg pain for over 10 years. She suffers form leg pain which extends into the foot, more so on the left. She has been treated with many forms of conservative care including physiotherapy, pain medication, and epidural steroid injections, all without relief. She was contemplating surgical intervention prior to presenting for high power laser therapy (HPLT).

CLINICAL EXAMINATION:

Neurological Exam:

DTR 2-/2 and symmetrical at the patella, achilles reflexes are 2/2 and symmetrical. All myotomes including EHL's are 5/5. Circumferential mensuration of the legs and calves were symmetrical and negative for long standing atrophy. Sensation to pinprick was intact. Babinski sign was flexor. She was able to heel and toe walk without difficulty.

Orthopedic Examination:

Straight leg raising was 90 degrees and negative for root tension signs. There was exquisite tenderness in the left Sciatic notch. There was also significant tenderness in the left sacroiliac joint at the superior pole. There was focal tenderness over the spinous process at L5. Flexion/ extension provocation testing reveled compete centralization of pain from the lower extremity as well as the left Sciatic notch with hyperextension of the lumbar spine. Flexion precipitated radiation into the left lower extremity. Sitting SLR with neck flexion and Valsalva's maneuver revealed increased pain in the left leg below the knee. Orthokinetic evaluation of the weight bearing patient reveled bilateral subtalar pronation with mild inferiority of the right hemi-pelvis. There was only minimal tenderness in the periarticular myofascial tissues of the hip joints bilaterally.

IMAGING/ MRI:

T1 &T2 weighted images in the saggital and transaxial planes were reviewed. There was disc desiccation at L3/4, L4/5, and L5/S1. There was disc a small disc protrusion at L3/4 with effacement of the thecal sac. There was also disc bulge at L4/5. Most interesting was a High intensity zone in the posterior annulus.

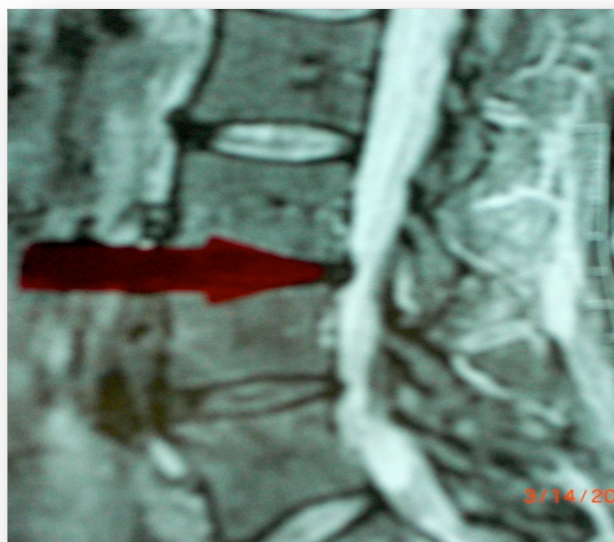


IMAGE 1—IMAGING/MRI

=====CASE REPORT=====

DIAGNOSIS:

Chronic left lumbosacral radiculopathy. Degenerative disc disease with L3/4 disc protrusion and “hiz” formation. Right sided kinetic chain dysfunction.

TREATMENT PLAN:

This patient was immediately cast in talar neutral for custom fabricated orthotics to correct her kinetic chain dysfunction. She began a trial with a right sided 5mm heel lift. She was placed in hyperextension. Once again, there was complete centralization of left sided leg pain as well as tenderness to the left Sciatic notch. She was treated with the high power laser beginning at 6 watts for 10 minutes to the lumbar spine and 10 minutes to the left Sciatic notch. The dosage was increased each visit until she was treated at 12 watts of power for 10 minutes to the lumbar spine and 10 minutes to the left Sciatic notch. She was treated for a total of 11 treatment sessions. Her results were quite remarkable are described by the patient in a video testimonial at the end of her treatment plan just prior to her returning to Germany.

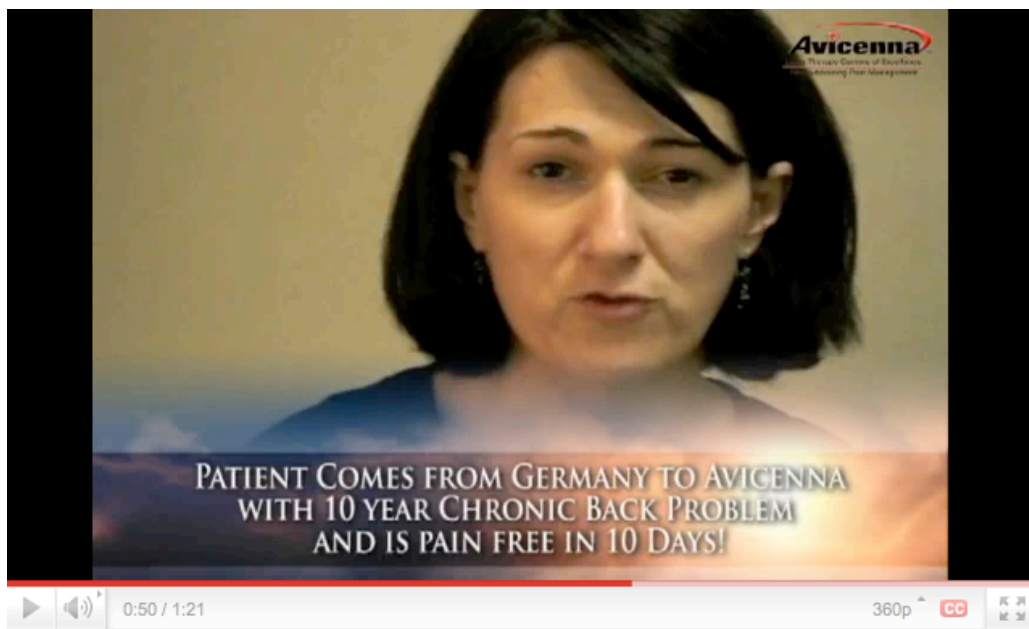


IMAGE 2—CLICK TO WATCH VIDEO ON YOUTUBE

DISCUSSION:

Laser therapy is classified as an actinotherapy which results in biostimulation of the chromophores inside the mitochondria of each cell (1,8). This photo-stimulation results in increased cellular metabolism, vasodilatation, and neo-capillary growth within the outer 1/3 of the annulus (9). Although the High Power Laser is warm, the results are photochemical and not thermal (8). Biostimulation translates into reduction of inflammation and increased lymphatic drainage. (5,6).

Regarding patients suffering from back and leg pain, the High Power Laser is thought to decrease inflammation of the disc pathology and nerve root as well as aid in nerve repair and regeneration. In order to achieve optimal healing and long term results, it has been found in a clinical setting that all biomechanical abnormal forces need to be removed so healing is not interrupted or compromised during gait, thus the need for orthotic correction is paramount in case management of the patient with long term back and leg complaints. This is proven by the facts of this case which reflect chronic long standing back and leg pain of 10 years duration which was refractive to all forms of traditional case management and then astoundingly was resolved within a 2 week period, with orthotic gait correction and high power laser therapy.

=====CASE REPORT=====

SUMMARY:

High Power Laser Therapy has the ability to reach deep within the body when compared to Low Level Laser Therapy (8). When used in a patient whose biomechanical abnormalities have been corrected, the results achieved seem to be long term in nature especially when compared to all other forms of traditional and alternative care. This may also be due to the fact that laser energy appears to also bio-stimulate collagen and fibroblast growth which would enhance the tensile strength of the annular fibers of the degenerative disc patient (1,2,3,4).

REFERENCES:

- (1) Effects of infrared laser exposure in a cellular model of wound healing. Skopin M and Molitor S, Dept. of Bioengineering, University of Toledo, Toledo OH.
- (2) Mester E, Mester AF, Mester A (1985) The Biomedical effects of laser application. *Lasers Surg. Med.* 5:31-39.
- (3) The influence of low level infra red laser therapy on the regeneration of cartilage tissue. P Lievens, Ph. Van der Veen.
- (4) Therapeutic low energy laser improves the mechanical strength of repairing medial collateral ligament. Fung DT, Ng GY, Leung MC, Tay DK, *Lasers Surg Med.* 2002; 31: 91-96.5) Double-blind randomized study evaluating regeneration of the rat transected sciatic nerve after suturing and postoperative low-power laser treatment. *Journal of Reconstructive microsurgery.* 2001; 17 (2): 133-137. Shamir MH, Rochkind S, Sandbank J, Alon M.
- (5) Effects of laser irradiation on the spinal cord for the regeneration of crushed peripheral nerve in rats. *Lasers in Surgery and Medicine* 2001, 28(3): 216-219. Rochkind S, Nissan M, Alon M et al.
- (6) Assessment of laser therapy for late postoperative pain after lumbar fusion surgery and for pain and wound
- (7) healing after acute traumatic injury- preliminary results. Biyani A, Skie M, Goel V, Ciocanel D, University of Toledo School of Medicine.
- (8) Class IV “High Power” laser therapy in Chiropractic and rehabilitation. Wertz R., *Dynamic Chiropractic-* 2006 vol. 24, issue 23.
- (9) Vascularization of the intervertebral disc in pathological conditions. Moore R, University of Adelaide, Feb. 1995.